



Predictive value of the specific radiographic signs at panoramic radiography indicating possible close relationship of posterior teeth and surrounding anatomical structures: A CBCT study

Prediktivna vrednost radiografskih znakova ortopantomografije koji ukazuju na moguću bliski odnos bočnih zuba sa okolnim anatomskim strukturama: CBCT studija

Aleksandar Djordjević*, Jelena Todić*†, Zoran Arsić*‡, Aleksandra Ilić*†, Radovan Jovanović*§, Zoran Vlahović*||

*University of Priština/Kosovska Mitrovica, Faculty of Medical Sciences, Department of Dentistry, Kosovska Mitrovica, Serbia; Clinical Hospital Center Kosovska Mitrovica, †Clinic for Prosthodontics, ‡Clinic for Periodontology, §Clinic for Endodontics, ||Clinic for Oral Surgery, Kosovska Mitrovica, Serbia

Abstract

Background/Aim. In planning the extraction of posterior teeth, it is necessary to determine their position and correlation with the surrounding anatomical structures. The aim of this study was to perform Cone Beam Computed Tomography (CBCT) analysis in order to evaluate the predictive value of specific orthopantomography (OPT) radiographic signs in determining the proximity of posterior upper teeth to the maxillary sinus and lower teeth to the mandibular canal. **Methods.** In a prospective study, 460 cases out of 423 patients were analyzed. Seven OPT radiographic signs were assessed to determine the correlation of the third molars to the mandibular canal, while five radiographic signs were followed to determine the correlation of the maxillary sinus floor to the upper posterior teeth. For each OPT radiographic sign, a precise analysis of the axial slices of the CBCT was performed. **Results.** Interruption of the white line is a radiographic sign showing statistically significant interruption of the integrity of the mandibular canal on the CBCT axial slices ($p = 0.002$). Also, diversion of the inferior alveolar canal at

the axial sections showed statistically significant interruption of the continuity of the mandibular canal ($p = 0.003$). A radiographic sign, Darkening of the root, showed superimposition of the anatomical structures, a close relationship with the tooth but often with preserved mandibular canal integrity ($p < 0.001$). Absence of *lamina dura*, interruption of the maxillary sinus floor's cortex, and projection of the root apices in the sinus cavity were radiographic signs that were statistically the most commonly associated with interruption of maxillary sinus integrity on CBCT axial slices ($p < 0.001$). **Conclusion.** The results of our study indicate that the presence of certain radiographic signs on the OPT may have predictive significance. The exact relationship between anatomical structures and posterior teeth cannot be accurately estimated on OPT. The precise position of the molars and correlation to the mandibular canal and the maxillary sinus can be accurately determined by CBCT imaging.

Key words: radiography, panoramic; cone beam computed tomography; mandible; maxillary sinus.

Apstrakt

Uvod/Cilj. U planiranju ekstrakcije bočnih zuba neophodno je odrediti njihov tačan položaj i odnos sa okolnim anatomskim strukturama. Ciljevi istraživanja bili su izvršiti procenu prediktivne vrednosti radiografskih znakova ortopantomografije i utvrditi značaj *Cone Beam Computed Tomography* (CBCT) u određivanju odnosa bočnih zuba sa mandibularnim kanalom u donjoj vilici i odnosa bočnih zuba sa maksilarnim sinusom u gornjoj vilici. **Metode.** U prospek-

tivnoj studiji analizirano je 460 slučajeva od 423 pacijenta. Na ortopantomografskim snimcima praćeno je sedam radiografskih znakova za određivanje odnosa bočnih zuba sa mandibularnim kanalom dok je pet radiografskih znakova praćeno za određivanje odnosa poda maksilarnog sinusa sa korenovima bočnih zuba. Za svaki radiografski znak vršena je precizna CBCT analiza na aksijalnim preseccima. **Rezultati.** Prekid bele linije je radiografski znak koji je na aksijalnim preseccima statistički značajno pokazivao prekide kontinuiteta mandibularnog kanala ($p = 0.002$). Skretanje kanala na aksijal-

nim preseccima pokazao statistički značajno čest prekid kontinuiteta mandibularnog kanala ($p = 0.003$). Radiografski znak zatamnjenja korenova pokazao je superponiranje anatomskih struktura, blizak odnos sa bočnim zubom ali često bez prekida kontinuiteta ($p < 0.001$). Odsustvo lamine dure, prekid kontinuiteta poda maksilarnog sinusa i projekcija vrha korena u lumen sinusa su radiografski znaci koji su statistički najčešće bili povezani sa prekidom kontinuiteta poda maksilarnog sinusa na aksijalnim preseccima ($p < 0.001$). **Zaključak.** Rezultati naše studije pokazali su da prisustvo određenih radio-

grafskih znakova na ortopantomografskim snimcima može imati prediktivni značaj. Takođe, na ortopantomografskim snimcima se ne može sa sigurnošću proceniti tačan odnos anatomskih struktura i bočnih zuba. Precizan položaj bočnih zuba u odnosu na mandibularni kanal i maksilarni sinus moguće je izvršiti na trodimenzionalnim snimcima CBCT.

Ključne reči:
ortopantomografija; tomografija, kompjuterizovana, konusna; mandibula; maksilarni sinus.

Introduction

In planning posterior teeth extraction, it is necessary to determine their exact position and relationship with the surrounding anatomical structures to prevent intraoperative and postoperative complications^{1,2}.

During preoperative preparation and planning of the extraction of the lower molars, it is essential to determine the exact position of the tooth and its relationship with the mandibular canal to avoid damaging the neurovascular contents of the mandibular canal^{3,4}. The particular importance for the upper posterior teeth extraction is the position of the tooth root apices and their relation to the floor of the maxillary sinus^{5,6}.

The most commonly used radiographic method for analyzing the posterior teeth position and the relationship with mentioned anatomical structures is orthopantomography (OPT)^{7,8}. On OPT images, referring the relationship of the posterior teeth to the surrounding anatomical structures for diagnosis, treatment plan, and preoperative preparation were analyzed^{9,10}.

Rood and Shehab¹¹ recommended altogether seven radiographic signs with the aim of determining the correlation of the posterior tooth and the mandibular canal on the OPT. Four of them occur on the tooth (darkening of the root, deflected roots, narrowing of the root, dark and bifid root) and the other three on the canal (interruption of the white line(s), diversion of the inferior alveolar canal, narrowing of the inferior alveolar canal).

According to Lopes et al.¹², for evaluating the relationship between the upper molars and the maxillary sinus floor, the presence or absence of the following radiographic signs should be followed: projection of the root apices in the sinus cavity, interruption of the maxillary sinus floor's cortex, *lamina dura*, darkening of the root apical region, upward curving of the sinus floor enveloping the tooth root partially or completely.

Cone Beam Computed Tomography (CBCT) has been widely used in dentistry in recent years, more than the conventional computed tomography (CT), due to lower radiation dose^{13,14}. However, higher radiation dose compared to OPT, additional costs, and lesser availability were responsible that CBCT has not been introduced as a routine additional diagnostic method^{15,16}.

The aim of this study was to perform CBCT analysis in order to evaluate the predictive value of the specific OPT radiographic signs used in determining the proximity of poste-

rior upper teeth to the maxillary sinus and lower teeth to the mandibular canal.

Methods

This prospective study was conducted at the Department of Dentistry, Faculty of Medical Sciences, University of Priština/Kosovska Mitrovica, on a sample of 423 patients (460 cases analyzed). A radiographic sign on OPT was identified as an inclusion criterion for the study. The patients identified with the radiographic sign on OPT were referred for CBCT imaging. The exclusion criteria for the study were relative or absolute contraindication for radiographic imaging, unclear images, and the absence of mandibular canal on OPT or CBCT (plexiform canal). Written informed consent was obtained from all participants for their data to be used in the study.

All of the panoramic radiographs were taken with Sirona Orthophos XG3D (Dentsply Sirona, USA), while the Sidexis XG 2.61 software, recommended by Sirona Dental System GmbH, was used to analyze the images. The Cone Beam CT scanner was Cranex 3Dx (Sorodex, KaVo). The field of view was 50 × 50 mm, 90 kVp, 6.1-sec exposure length with a radiation dose of 320.8 mGy/cm². The software used to analyze the three-dimensional radiographic images was the OnDemand3D CD viewer.

Having identified the radiographic sign on OPT, the marking and the mapping of the mandibular canal were performed using the CBCT software (Figures 1 and 2). Analysis was performed on the CBCT axial sections (Figure 2). Depending on the findings, the case was classified into one out of seven groups (twelve subtypes) based on the classes formed according to Maglione et al.¹⁷ CBCT classification (Table 1).

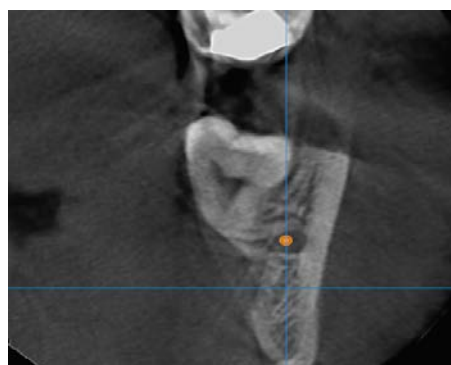


Fig. 1 – The marking and the mapping of mandibular canal.

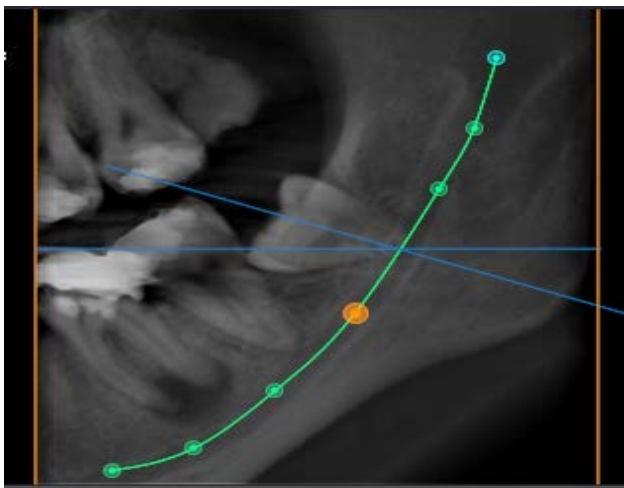


Fig. 2 – The axial cross-section analysis of the Cone Beam Computed Tomography (CBCT) image shows preserved diameter of the mandibular canal (class 2, subtype 2b).

To evaluate the relationship between the maxillary molars and maxillary sinus floor, radiographic signs, according to the criteria established by Lopes et al.¹², were used.

Having identified the radiographic sign using OPT, a detailed analysis was performed on CBCT slices. Depending on the relationship of upper posterior teeth and maxillary sinus floor on CBCT, cases were classified into one out of four groups based on the classes according to the recommendations of Shahbazian et al.⁶. CBCT classifications were used for the precise definition of the three-dimensional topographic relationship between anatomic structures (Table 2).

Statistical data analysis

The proportions of radiographic signs between the classes were analyzed using the χ^2 -test. All *p* values less than 0.05 were considered significant. The Statistical Package for the Social Science Program (version 22, SPSS Inc., Chicago, IL, USA) was used in the statistical analysis.

Table 1
Cone Beam Computed Tomography (CBCT) radiological classification for determining the relationship of mandibular canal and the lower posterior teeth by Maglione et al.¹⁷

Classes	Subtypes
Class 0: the mandibular canal is not visible on the images (plexiform canal).	/
Class 1: the mandibular canal runs apically or buccally with respect to the tooth but without touching it (the cortical limitations of the canal are not interrupted).	1A: the distance IAN/tooth is greater than 2 mm. 1B: the distance IAN/tooth is less than 2 mm
Class 2: the mandibular canal runs lingually with respect to the tooth but without touching it (the cortical limitations of the canal are not interrupted).	2A: the distance IAN/tooth is greater than 2 mm. 2B: the distance IAN/tooth is less than 2 mm.
Class 3: the mandibular canal runs apical or buccal touching the tooth.	3A: in the point of contact, the mandibular canal shows a preserved diameter. 3B: in the point of contact, the mandibular canal shows a smaller calibre and/or an interruption of the corticalization.
Class 4: the mandibular canal runs lingually touching the tooth.	4A: in the point of contact, the mandibular canal shows a preserved diameter. 4B: in the point of contact, the mandibular canal shows a small calibre and/or an interruption of the corticalization.
Class 5: the mandibular canal runs between the roots but without touching them.	5A: the distance IAN/tooth is greater than 2 mm. 5B: the distance IAN/tooth is less than 2 mm.
Class 6: the mandibular canal runs between the roots touching them.	6A: in the point of contact, the mandibular canal shows a preserved diameter. 6B: in the point of contact, the mandibular canal shows a small calibre and/or an interruption of the corticalization.
Class 7: the mandibular canal runs between fused roots	/

IAN – inferior alveolar nerve.

Table 2
Cone Beam Computed Tomography (CBCT) radiological classification for determining the relationship of the maxillary sinus floor and upper posterior teeth

Class 1:	when there was a distinct space between the root tip and the sinus floor
Class 2:	when the roots were in close contact with the floor of the maxillary sinus (< 0.5 mm away)
Class 3:	when the roots were projected onto the sinus but were actually lateral or medial to it
Class 4:	when the roots were protruded into the maxillary sinus cavity.

Results

The total of 460 cases out of 423 patients with an identified OPT radiographic sign were analyzed. The proximity of posterior teeth to the maxillary sinus was analyzed on 234 (50.87%) images and 226 (49.13%) radiographic images implied an analysis of the inferior alveolar nerve canal position in relation to mandibular molars.

Results of OPT and CBCT analysis of the relationship between the mandibular canal and the molar teeth

Taking into account the total number of analyzed images, 13.3% or 30 cases belong to the first and second class with subclasses (1a, 1b, 2a, 2b). The statistical analysis revealed that radiographic sign 'Darkening of the root' was statistically significantly more frequent ($p < 0.001$) in cases without direct contact of anatomic structures (Classes 1a, 1b, 2a, 2b) comparing to the other classes (Figure 3).

The finding of radiographic sign 'Narrowing of the inferior alveolar canal' was confirmed in 18.5% of cases in the Class 3a according to the CBCT. Narrowing of the inferior

alveolar canal was statistically significantly more frequent in the Class 3a comparing the other classes ($p = 0.050$).

The radiographic sign 'Interruption of the white line' was confirmed in 38% of patients having a CBCT finding corresponding to the Class 3b. The radiographic sign 'Interruption' of the white line was statistically significantly more frequent in the Class 3b than in the other classes ($p = 0.002$).

Diversion of the inferior alveolar canal was confirmed in 23.5% of subjects belonging to Class 3b. The frequency of this finding was statistically significantly different in the Class 3b compared to the other classes ($p = 0.003$).

Radiographic sign 'Darkening of the root' was confirmed in 52.4% of cases in the Class 4a. There was statistically significantly more frequency in the Class 4a compared to the presence in other classes ($p = 0.002$) (Figure 4).

In determining the bucco-mesial localization of the mandibular canal, the frequency of lingual localization of the mandibular canal was observed in 59 cases, while the occurrence of buccal-localization appeared in 50 cases. In 117 cases, the apical localization of the mandibular canal was observed.

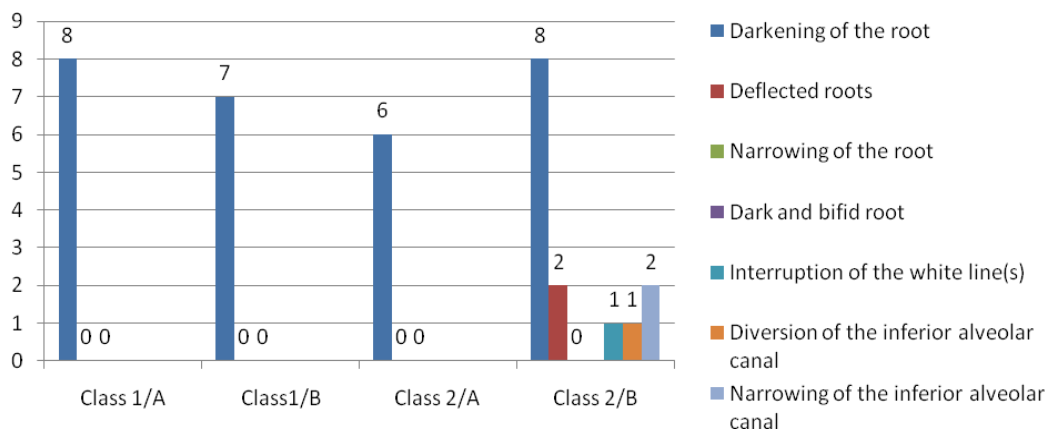


Fig. 3 – Frequency of radiographic signs in the first and second class (without the direct contact of anatomical structures).

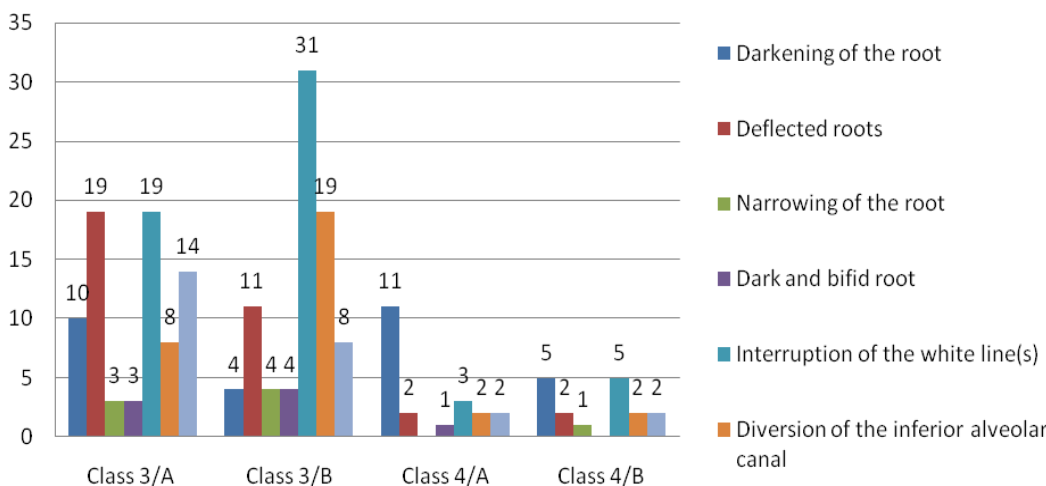


Fig. 4 – Frequency of radiographic signs in the third and fourth class (with the direct contact of anatomical structures).

The OPT and CBCT results analysis of the relationship between the roots of maxillary teeth and the maxillary sinus

The 'Darkening of the root' apical region was confirmed in 71% of subjects in the group with Type 1 finding on the CBCT. It was statistically significantly more frequent in the group with Type 1 findings on the CBCT compared to other findings on the CBCT ($p = 0.007$).

Upward curvature of the sinus floor enveloping the tooth root partially or completely was confirmed in 39% of subjects in the group with Type 2 finding on the CBCT and was statistically significantly more frequent in this group compared to other types ($p < 0.001$).

Interruption of the maxillary sinus floor's cortex was present in 15% of patients in the group with Type 4 findings on the CBCT. Interruption of the maxillary sinus floor's cortex was statistically significantly more frequent in the group with Type 4 findings on the CBCT compared to other types ($p < 0.001$).

The presence of radiographic findings 'Absence of *lamina dura*' was also diagnosed in 15% of patients in the group with Type 4 findings on the CBCT and was significantly more common than other types ($p < 0.001$).

Projection of root apices in the sinus cavity was confirmed in 66 (55%) cases in the group with Class 4 findings on the CBCT. Projection of the root apices in the sinus cavity was statistically significantly more frequent in the group with Class 4 findings on the CBCT compared to other types (Table 3).

and 'Interruption of the white line' are associated with an increased risk of postoperative neurosensory complications. Our study found the frequent interruption of the mandibular canal diameter by monitoring CBCT axial sections for the OPT radiographic sign diversion of the inferior alveolar canal. Likewise, the OPT radiographic sign 'Interruption of the white line' showed statistically significant interruptions of the mandibular canal diameter, confirmed by the CBCT analysis. This may be one of the reasons for more frequent neurosensory postoperative complications when these radiographic signs occur.

In our study, the presence of the radiographic sign 'Darkening of the root' indicated the superimposition of the evaluated anatomical structures in most cases. The axial section images confirmed high-frequency of the close relationship of the two anatomical structures, but with preserved mandibular canal continuity.

According to the analogous clinical trials, assessing the importance of this radiographic sign, a frequent close relationship and direct contact between anatomical structures can be seen on radiograph images, as well as the appearance of clinical postoperative complications, such as paraesthesia^{10, 20}.

The American Dental Association (ADA) study¹⁹ recognizes superimposition as a sign leading to neurosensory complications in some cases. Their research has been supported by the findings of other authors indicating the presence of two or more signs on panoramic radiography and the deep horizontally impacted mandibular molar represent factors associated strongly with the proximity of the impacted

Table 3

The frequency of orthopantomography (OPT) radiographic signs in classes based on the classification of Shahbazian et al.²⁵ after analysis on Cone Beam Computed Tomography (CBCT)

Radiographic signs	The position of the floor of the maxillary sinus at the axial cross-section				Total n (%)
	Class 1 n (%)	Class 2 n (%)	Class 3 n (%)	Class 4 n (%)	
Total	17 (5.3)	83 (26.1)	98 (30.8)	120 (37.7)	318 (100)
Projection of the root apices in the sinus cavity	2 (11.8)	6 (7.2)	14 (14.3)	66 (55.0)*	88 (27.7)
Interruption of the maxillary sinus floor's cortex	0 (0)	2 (2.4)	4 (4.1)	18 (15.0)*	24 (7.5)
Absence of <i>lamina dura</i>	0 (0)	3 (3.6)	0 (0)	18 (15.0)*	21 (6.6)
Darkening of the root apical region	12 (70.6)	40 (48.2)	60 (61.2)*	14 (11.7)	126 (39.6)
Upward curving of the sinus floor enveloping the tooth root partially or completely	3 (17.6)	32 (38.6)*	20 (20.4)	4 (3.3)	59 (18.6)

*there is a statistically significant difference in the frequency of radiographic sign compared to other classes ($p < 0.001$).

Discussion

Several studies, which have dealt with a relationship among different anatomical structures on OPT images, have shown that the presence of certain radiographic indicators indicates a possibility of postoperative complications^{18, 19}.

The use of radiographic signs during the analysis of two-dimensional OPT images may point out a close relationship between the mandibular canal and impacted third molars, based on the recommendations of Rood and Shehab¹¹. The authors claim that radiographic signs referring to diversion of the inferior alveolar canal, 'Darkening of the root',

tooth to the mandibular canal and an increased risk of complications²⁰⁻²⁴. Our study showed that it is impossible to determine the bucco-oral localization of the mandibular canal on the OPT, while at the axial sections of CBCT it is possible to determine the exact position and precise interrelation of the anatomical structures.

Lopes et al.¹² used similar OPT radiographic signs for evaluating the relationship of the upper posterior teeth with the maxillary sinus. The findings of their research indicate that the presence or absence of some OPT radiographic signs may have a predictive value in expectation of the occurrence of oro-antral communication during the procedure. The re-

sults of our study indicate that the absence of the *lamina dura*, interruption of the maxillary sinus floor's cortex, and projection of the root apices in the sinus cavity represent radiographic signs that are most frequently associated with the interruption of the maxillary sinus floor at axial sections on CBCT. Also, the findings indicate the possibility of the appearance of two or more radiographic signs in the same case. The study showed that OPT radiographic sign 'Interruption of the maxillary sinus floor's cortex', combined with the 'Absence of the *lamina dura*' positively correlated with the cortical interruption of the sinus floor at the axial sections of the CBCT.

According to the CBCT analysis in our study, the 'Interruption of the white line' and the diversion of the inferior alveolar canal at the OPT are radiographic signs pointing out a frequent interruption of the mandibular canal. The radiographic sign 'Darkening of the root' shows the superimposition of the anatomical structures, proximity of the mandibular canal and posterior teeth, but often with

preserved diameter. The absence of the *lamina dura*, the interruption of continuity of the maxillary sinus floor, and projection of the apex of the root into the sinus lumen are the radiographic signs most commonly associated with the interruption of cortical bone of the maxillary sinus floor. The OPT radiographic signs may be predictive, but the precise position of the posterior teeth with the mandibular canal or maxillary sinus can only be determined on CBCT radiographs.

Conclusion

The results of our study indicate that the presence of certain radiographic signs on the OPT may have predictive significance. The exact relationship between anatomical structures and posterior teeth cannot be accurately estimated on the OPT since the precise position of the molars and correlation to the mandibular canal and the maxillary sinus can be accurately performed only on the CBCT.

R E F E R E N C E S

1. *Fragiskos FD*. Oral Surgery. In: *Fragiskos FD*, editor. Perioperative and Postoperative Complications. Chapter 8. Berlin, Heidelberg: Springer-Verlag; 2007. p. 181–203.
2. *Bouloux GF, Steed MB, Pericaccante VJ*. Complications of third molar surgery. *Oral Maxillofac Surg Clin North Am* 2007; 19(1): 117–28. vii.
3. *Gallesio C, Berrone M, Ruga E, Boffano P*. Surgical extraction of impacted inferior third molars at risk for inferior alveolar nerve injury. *J Craniofac Surg* 2010; 21(6): 2003–7.
4. *Abu-El Naaj I, Braun R, Leiser Y, Peled M*. Surgical approach to impacted mandibular third molars - operative classification; *J Oral Maxillofac Surg* 2010; 68(3): 628–33.
5. *Ok E, Güngör E, Colak M, Altunsoy M, Nur BG, Ağlarci OS*. Evaluation of the relationship between the maxillary posterior teeth and the sinus floor using cone-beam computed tomography. *Surg Radiol Anat* 2014; 36(9): 907–14.
6. *Shahbazian M, Vandevoude C, Wyatt J, Jacobs R*. Comparative assessment of periapical radiography and CBCT imaging for radiodiagnostics in the posterior maxilla. *Odontology* 2015; 103(1): 97–104.
7. *Vlavić Z, Đorđević A, Đorđević F, Stanišić J* Using Cone Beam Computed Tomography in planning the extraction of impacted third molars. *Praxis Medica* 2016; 45(2): 39–43. (Serbian)
8. *Jhamb A, Dolas RS, Pandilvar PK, Mohanty S*. Comparative efficacy of spiral computed tomography and orthopantomography in preoperative detection of relation of inferior alveolar neurovascular bundle to the impacted mandibular third molar. *J Oral Maxillofac Surg* 2009; 67(1): 58–66.
9. *Saraswati FK, Balajirao B, Mamatha GP*. Clinical and orthopantomographic evaluation of mandibular third molar. *Contemp Clin Dent* 2010; 1(1): 27–30.
10. *Güllicher D, Gerlach KL*. Sensory impairment of the lingual and inferior alveolar nerves following removal of impacted mandibular third molars. *Int J Oral Maxillofac Surg* 2001; 30(4): 306–12.
11. *Rood JP, Shehab BA*. The radiological prediction of inferior alveolar nerve injury during third molar surgery. *Br J Oral Maxillofac Surg* 1990; 28(1): 20–5.
12. *Lopes LJ, Gamba TO, Bertinato JV, Freitas DQ*. Comparison of panoramic radiography and CBCT to identify maxillary posterior roots invading the maxillary sinus. *Dentomaxillofac Radiol* 2016; 45(6): 20160043.
13. *Peker I, Sarikir C, Alkurt MT, Zor ZF*. Panoramic radiography and cone-beam computed tomography findings in preoperative examination of impacted mandibular third molars. *BMC Oral Health* 2014; 14: 71.
14. *Sharan A, Madjar D*. Correlation between maxillary sinus floor topography and related root position of posterior teeth using panoramic and cross-sectional computed tomography imaging. *Oral Surg Oral Med Oral Pathol Oral Radiol Endod* 2006; 102(3): 375–81OS.
15. *Pallavi S, Anuradha P*. Assessment of proximity of impacted mandibular third molar roots to the mandibular canal using intraoral periapical radiograph and cone-beam computerized tomography: A comparative study. *Int Dent Med J Adv Res* 2015; 1: 1–5.
16. *Altındağ A, Arsever H, Borahan O, Akyol M, Orhan K*. Incidental Findings in Cone-Beam Computed Tomographic Images: Calcifications in Head and Neck Region. *Balk J Dent Med* 2017; 21: 100–7.
17. *Maglione M, Costantinides F, Bazzeocchi G*. Classification of impacted mandibular third molars on cone-beam CT images. *J Clin Exp Dent* 2015; 7(2): e224–31.
18. *Szalma J, Lempel E, Jeges S, Olasz L*. Darkening of third molar roots: panoramic radiographic associations with inferior alveolar nerve exposure. *J Oral Maxillofac Surg* 2011; 69(6): 1544–9.
19. *Bell GW*. Use of dental panoramic tomographs to predict the relation between mandibular third molar teeth and the inferior alveolar. Radiological and surgical findings, and clinical outcome. *Br J Oral Maxillofac Surg* 2004; 42(1): –7.
20. *Szalma J, Lempel E, Jeges S, Szabó G, Olasz L*. The prognostic value of panoramic radiography of inferior alveolar nerve damage after mandibular third molar removal: retrospective study of 400 cases. *Oral Surg Oral Med Oral Pathol Oral Radiol Endod*. 2009; 109(2): 294–302.
21. *Monaco G, Montevicchi M, Bonetti GA, Gatto MR, Checchi L*. Reliability of panoramic radiography in evaluating the topographic relationship between the mandibular canal and impacted third molars. *J Am Dent Assoc* 2004; 135(3): 312–8.
22. *Gomes AC, Vasconcelos BC, Silva ED, Caldas Ade F Jr, Pita Neto IC*. Sensitivity and specificity of pantomography to predict inferior alveolar nerve damage during extraction of impacted lower third molars. *J Oral Maxillofac Surg* 2008; 66(2): 256–9.

23. *Shabbazian M, Vandewoude C, Wyatt J, Jacobs R.* Comparative assessment of panoramic radiography and CBCT imaging for radiodiagnostics in the posterior maxilla. *Clin Oral Investig* 2014; 18(1): 293–300.
24. *Tian XM, Qian L, Xin XZ, Wei B, Gong Y.* An Analysis of the Proximity of Maxillary Posterior Teeth to the Maxillary Sinus Using Cone-beam Computed Tomography. *J Endod* 2016; 42(3): 371–7.

Received on October 1, 2019

Revised on February 28, 2020

Accepted on February 28, 2020

Online First March, 2020